

Biochemical and clinical analysis of accumulated glycolipids in symptomatic heterozygotes of angiokeratoma corporis diffusum (Fabry's disease) in comparison with hemizygotes

Isao Hozumi,^{1,*} Masatoyo Nishizawa,^{2,*} Toshio Ariga,^{3,†} and Tadashi Miyatake^{4,*}

Department of Neurology, Brain Research Institute,* Niigata University, Asahimachi 1, Niigata 951, Japan, and Department of Membrane Biochemistry,† The Tokyo Metropolitan Institute of Medical Science, Honkomagome, Bunkyo-ku, Tokyo 113, Japan

Abstract Angiokeratoma corporis diffusum (Fabry's disease) is an X-linked disorder of glycosphingolipid catabolism. Heterozygous females, although usually asymptomatic, are occasionally as severely afflicted as hemizygous males; recently we identified a heterozygous patient with cardiomyopathy and severe pain in the extremities. In order to elucidate the difference of the clinical features, we analyzed the glycolipid composition of the heart, liver, and kidney obtained from the patient and from a hemizygote. Gas-liquid chromatography revealed that globotriaosylceramide (Gb₃) was markedly increased in the heart (32.4 times higher than control) and increased to a lesser extent in the liver and kidney (3.74 and 6.79 times, respectively). The pattern of Gb₃ accumulation in the heterozygote, where the highest increases were seen in the heart, was distinct from that in the hemizygote, where elevated levels of Gb₃ and Ga₂ were found in the kidney. Furthermore, the α -galactosidase activity in the heart, liver, and kidney of the heterozygote was 17%, 26%, and 36%, respectively, of normal controls, which correlated well with the accumulation of glycosphingolipid in the heart and with the disease's clinical manifestations. Two other hemizygotic patients, who were identified by low α -galactosidase activities, demonstrated the cardiac involvement. — **Hozumi, I., M. Nishizawa, T. Ariga, and T. Miyatake.** Biochemical and clinical analysis of accumulated glycolipids in symptomatic heterozygotes of angiokeratoma corporis diffusum (Fabry's disease) in comparison with hemizygotes. *J. Lipid Res.* 1990. **31**: 335–340.

Supplementary key words Fabry's disease • α -galactosidase • glycosphingolipid • heterozygote • gas-liquid chromatography

Fabry's disease is an X-linked disorder of glycosphingolipid catabolism due to a deficiency of the lysosomal enzyme, α -galactosidase A. The diagnosis is biochemically confirmed by demonstration of marked accumulation of glycolipids, particularly globotriaosyl ceramide (Gb₃) in urinary sediment, cultured fibroblasts, heart, kidney,

ganglion cells, and most other tissues. Progressive glycolipid deposition leads to skin lesions, renal disease, and a painful polyneuropathy. Most heterozygous females have intermediate levels of α -galactosidase A and Gb₃ accumulation and are almost asymptomatic (1). However, there have been reports of heterozygous carriers in whom the symptoms were comparable to those observed in severely affected hemizygous patients (2–7). Colley et al. have reported lipid deposits in heterozygote kidney (8), but there have been no studies of the accumulated glycolipids in heterozygous females with this disorder. In a previous study, we identified a case of symptomatic Fabry's disease and reported that histochemical examination demonstrated marked glycolipid deposits in spinal and sympathetic ganglia, which were identified as Gb₃ and Ga₂ by gas-liquid chromatography (9). In this study we performed biochemical investigations of tissues obtained from the heterozygote and made comparisons between the hemizygote and the symptomatic heterozygote. In addition, we discuss the clinical manifestations of Fabry's disease in symptomatic heterozygotes.

Abbreviations: Gb₃, globotriaosylceramide; Ga₂, galabiosylceramide; ECG, electrocardiogram; SEP, sensory evoked potential; LacCer, lactosyl ceramide; 4-MU derivative, 4-methyl umbelliferyl derivative; GLC, gas-liquid chromatography; TLC, thin-layer chromatography.

¹Present address: Department of Neurology, Albert Einstein College of Medicine, Bronx, NY 10461.

²Present address: Department of Neurology, National Institute of Neuroscience, N. C. N. P., Kodaira, Tokyo 187, Japan.

³Present address: Department of Biochemistry and Molecular Biophysics, Medical College of Virginia, Richmond, VA 22298-0614.

⁴To whom reprint requests should be addressed at: Department of Neurology, Brain Research Institute, Niigata University, Asahimachi 1, Niigata 951, Japan.

MATERIALS AND METHODS

Brief case reports

Patient 1. A 50-year-old Japanese woman complained of anterior chest pain and fatigue. Her electrocardiogram (ECG) was indicative of apical hypertrophic cardiomyopathy. An endomyocardial biopsy showed vacuolar and granular deposit composed of myelin-like structures in myocardial cells. At the age of 55, her anterior chest pain and fatigue became severe, and she also developed pain in the extremities. She was diagnosed as symptomatic heterozygotic Fabry's disease by measurement of lysosomal enzyme activities in leukocytes (Table 1). She also developed interstitial pneumonia, disseminated intravascular coagulation, and cerebral hemorrhage, and subsequently died. She had neither skin lesions nor anhidrosis; chromosomal analysis revealed no abnormality, and her blood group type was O. Details of the cardiologic (10) and neurological (9) findings have been reported elsewhere.

Patient 2. A 27-year-old daughter of patient 1 was found to be a heterozygote of Fabry's disease by enzymological examination (Table 1). She was asymptomatic, and nerve conduction velocity and sensory evoked potential (SEP) were normal. However, her ECG already showed ST-T changes in leads II, III, and aVF.

Patient 3. An 18-year-old woman was discovered to have hypertension. At 21 years of age, her left eye lost sight because of ischemic optic neuropathy. She complained of severe headache and her cerebrospinal fluid showed pleocytosis. A renal biopsy was performed because of proteinuria and showed intracellular vacuolation. A diagnosis of Fabry's disease was substantiated by enzymological examination (Table 1). Her ECG and echocardiogram taken at age 26 were normal. However, isotopic myocardial scintigraphy revealed marked uptake of isotope in the apex of the heart. This finding was thought to correlate with the accumulation of glycolipid. She also had pains in

the extremities, especially after taking a bath. Her nerve conduction velocity and SEP were normal. Her brother was identified as having Fabry's disease.

Patient 4. A 20-year-old man was discovered to have proteinuria. From early childhood, he noticed anhidrosis. Renal function then deteriorated and he was maintained on chronic dialysis. The enzymatic examination and the increase of Gb₃ and Ga₂ in urinary sediments revealed that he had Fabry's disease. At the age of 41, he died of cerebral hemorrhage.

Estimation of accumulated neutral glycosphingolipids

Total lipids were extracted from 1 g of tissue, obtained from each patient or normal control, with 20 ml each of chloroform-methanol 2:1 and 1:2 (v/v). The combined lipid extracts were applied to a DEAE-Sephadex A-25 column (acetate form, 3 ml bed volume) and further eluted with 40 ml of chloroform-methanol-water 30:60:8 (by volume). The fraction that contained the neutral glycolipids was evaporated to dryness, dissolved in 6 ml of 0.2 N NaOH in methanol, and incubated at 40°C for 2 h in order to hydrolyze excess phospholipids. After neutralization with appropriate amounts of acetic acid, the liberated fatty acid esters were removed by the addition of n-hexane. Then 10 ml of chloroform and 4 ml of water were added and partitioned. The upper aqueous layer was removed and 4 ml of chloroform-methanol 1:1 (v/v) was added to the lower chloroform layer which contained crude neutral glycolipids (11). The mixture was partitioned. The upper phase, which contained impurities, was discarded. The lower phase was evaporated to dryness under a stream of nitrogen. Final purification of the glycolipids was achieved by preparative thin-layer chromatography (TCL) with chloroform-methanol-water 65:35:8 (by volume).

Quantitative analyses of globotriaosyl ceramide (Gb₃) and galabiosylceramide (Ga₂)

The regions on the plates corresponding to authentic samples of Gb₃ and lactosyl ceramide (LacCer) were scraped with a razor blade and the silica gel powder was applied to an Iatrobeds (0.2 g) column, which had been prewashed with 5 ml of methanol and then 5 ml of chloroform-methanol 2:1 and 1:2 (v/v). Glycolipids were eluted with 10 ml each of chloroform-methanol 2:1 and 1:2 (v/v). The eluates were combined and evaporated to dryness under a stream of nitrogen. Aliquots of glycolipid fractions, to which 5 μg of myoinositol was added as an internal standard, were methanolized with 200 μl of 3% (w/v) HCl (gas) in methanol at 75°C for 16 h. After removing the fatty acid methyl esters with n-hexane, the methanol layer was evaporated under a stream of nitrogen and dried under vacuum. The residue was then trimethylsilylated with 20 μl of hexamethyldisilazane-trimethylsilane-pyri-

TABLE 1. The α-galactosidase activity of leukocytes and fibroblasts

Subjects	α-Galactosidase Activity	
	Leukocytes	Fibroblasts
	<i>nmol/h · mg protein⁻¹</i>	
Patient 1	12.4	17.1
Patient 2	27.3	ND
Patient 3	34.5	ND
Normal controls	67.0 ± 16.2 n = 38	84.5 ± 21.8 n = 5

The activity was measured with 4-methyl-umbelliferyl α-D-galactoside. All other lysosomal enzyme activities (β-galactosidase, β-hexosaminidase A and B) measured were within normal range. Normal control values are expressed as mean ± SD; ND, not determined.

dine 2:1:5 (by volume) at 75°C for 7 min. An aliquot of this reaction mixture was injected into a gas chromatograph equipped with a 3% OV-1 column maintained at 175°C. Standard samples consisting of various amounts (5 to 30 µg) of globoside purified from pig erythrocyte membranes and 5 µg of myoinositol as an internal standard were also analyzed (12).

Measurement of lysosomal enzyme activities

Leukocytes were isolated from heparinized blood of the patient and sonicated three times in phosphate-buffered saline for 20 sec. Heart, liver, and kidney were homogenized with two volumes of distilled water, and then sonicated three times for 20 sec. Lysosomal enzyme activities were measured using 4-methylumbelliferyl (4-MU) derivatives as substrates (13), and α-galactosidase A

activities were determined with ³H-labeled Gb₃ as the natural substrate according to the method of Kobayashi, Shinnoh, and Kuroiwa (14).

RESULTS

In a heterozygous carrier (patient 1) and a hemizygous male (patient 4), two major glycolipids, Gb₃ and Ga₂, were found to be accumulated in heart, kidney, and liver (Fig. 1 and Table 2). The chemical structures of Gb₃ and Ga₂ were confirmed by carbohydrate analysis by gas-liquid chromatography (GLC) and thin-layer chromatography (TLC) with authentic glycolipids. The band corresponding to Ga₂ should also contain a small amount of LacCer. In normal controls, the band corresponding to ceramide disaccharide in liver and heart was mainly Lac-

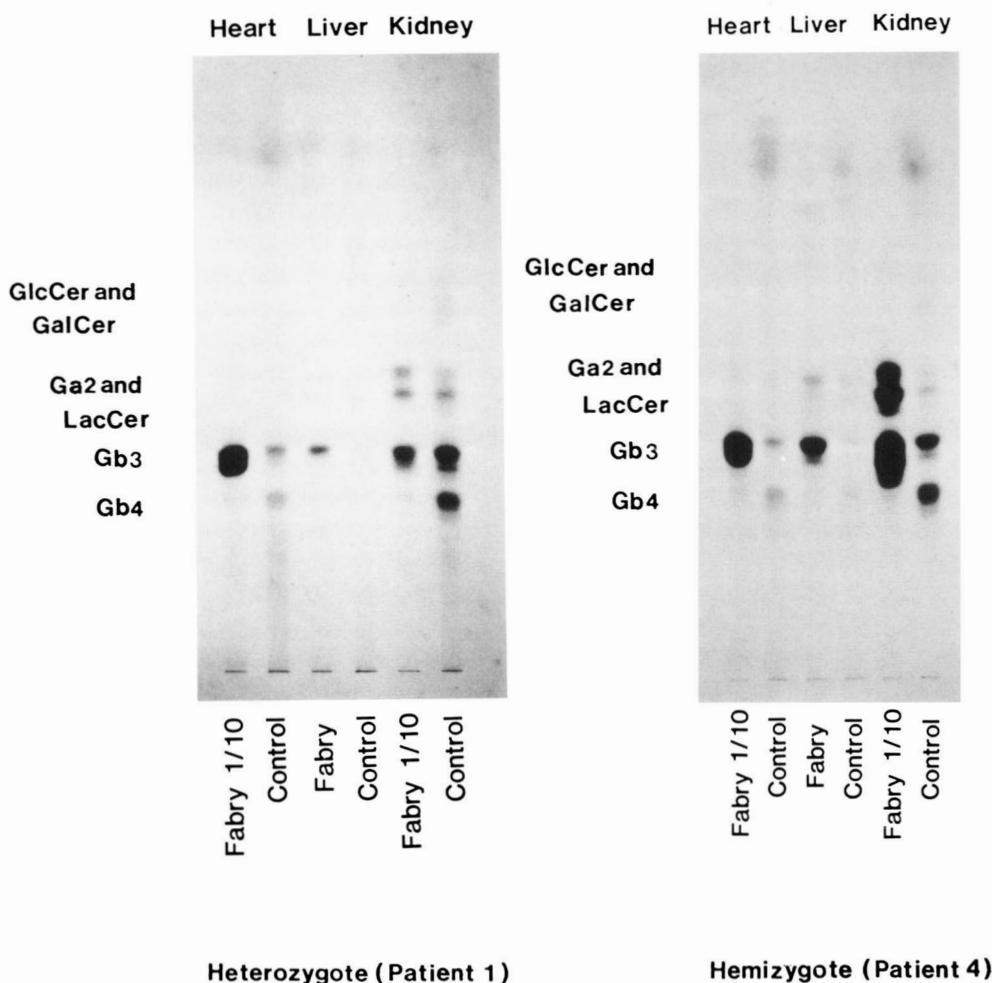


Fig. 1. Thin-layer chromatography (TLC) of neutral glycolipids of heart, liver, and kidney. Left panel: a heterozygote of Fabry's disease (patient 1) and control 1 (a 55-year-old female). One-tenth of the control amount of neutral glycolipids from heart and kidney of patient 1 was applied to the plate. The amount of Gb₃ is markedly increased in the heart of patient 1. Right panel: a hemizygote of Fabry's disease (patient 4) and control 2 (a 45-year-old male). One-tenth of the control amount of neutral glycolipids from heart and kidney of patient 4 was applied to the plate. Gb₃ and Ga₂ increased predominantly in the kidney of patient 4.

TABLE 2. Concentrations of Gb₃ and Ga₂ plus LacCer in patients 1 and 4 with Fabry's disease and in normal controls

Subject	Age	Sex	Heart		Liver		Kidney	
			Gb ₃	Ga ₂ + LacCer	Gb ₃	Ga ₂ + LacCer	Gb ₃	Ga ₂ + LacCer
	<i>yr</i>		<i>μg/g wet weight</i>					
Patient 1								
Heterozygote	55	F	3190	258	76.6	14.0	1440	784
Control 1	55	F	98.4	12.7	20.5	19.8	212	45.0
Patient 4								
Hemizygote	44	M	5290	621	317	59.3	11600	4060
Control 2	45	M	65.0	15.9	15.0	17.5	182	51.9

Cer, but the band in kidney also contained Ga₂ as previously reported (15). In the heterozygote, the amount of Gb₃ in heart, liver, and kidney was 32.4, 3.74, and 6.79 times greater, respectively, than that in normal controls, the heart thus showing the greatest amount (Table 2). Ga₂ was found to accumulate markedly in both kidney and heart.

In the hemizygous male, Gb₃ and Ga₂ progressively accumulated in heart, liver, and kidney. The amount of Gb₃ in the heart, liver, and kidney was 81.3-, 21.1-, and 63.7-fold, respectively, that of the normal control values. In the hemizygote, the greatest accumulation of Gb₃ was in the kidney, 2.2 times the amount in the heart (Table 2). Ga₂ was also markedly increased in the kidney, and to a lesser extent, in the heart and liver.

Table 3 shows the levels of α-galactosidase A activity in the heterozygous female. The levels of α-galactosidase activity in heart, liver, and kidney were 16.9%, 26.1% and 36.0%, respectively, of normal controls, when measured using the 4-MU derivative of α-galactoside as substrate, and 21.4%, 29.6%, and 39.5%, respectively, of control level when the natural substrate ³H-labeled Gb₃ was used. The residual activity of α-galactosidase was 18.5% in leukocyte and 20% in cultured fibroblasts of normal controls (Table 1). The residual activity of α-galactosidase activity in heart may lead to the marked accumulation of Gb₃ and Ga₂ and correlates well with the clinical cardiac involvement. The levels of other lysosomal enzymes were unchanged.

DISCUSSION

In Fabry's disease, most heterozygous females have either only mild symptoms, such as corneal opacities, or are almost completely asymptomatic throughout life (1). However, several heterozygotes have been reported to show the same clinical manifestations as those observed in hemizygous males (2-7). The present report is the first biochemical study of organs obtained from a symptomatic heterozygote. The accumulation of glycosphingolipids in the three organs studied correlated with the deficiency of α-galactosidase activities in those organs. The cardiac abnormalities may be caused by the remarkable accumulation of glycosphingolipids in the heart, which was more pronounced than in liver or kidney. It is probable that the cardiac impairments reported in other symptomatic heterozygotes are also related to the accumulation of glycolipids. Generally, the cardiac abnormalities develop during middle age, consistent with a slow accumulation of Gb₃ caused by α-galactosidase deficiency. However, we have also demonstrated some cardiac involvement in two young heterozygotes (patients 2 and 3) who had α-galactosidase activities in leukocytes that were approximately 50% of normal. Patient 1 had residual α-galactosidase activities that were less than the expected 50% of normal in all tissues examined, but they varied considerably from one organ to another. In hemizygotes, of course, α-galactosidase activities in all tissues are much lower than in our heterozygote patient (14-16).

TABLE 3. The α-galactosidase activity of various organs obtained from patient 1

Organ	4-MU-α-Galactoside		³ H]Gb ₃	
	Patient 1	Controls, n = 3	Patient 1	Controls, n = 3
Heart	8.4	49.7 ± 4.6	1.45	6.77 ± 1.21
Liver	22.2	84.9 ± 24.1	2.74	9.25 ± 2.36
Kidney	32.4	90.3 ± 17.8	4.62	11.7 ± 2.07

The activity was measured with 4-methyl umbelliferyl-α-D-galactoside and [³H]Gb₃. Normal controls are expressed as mean ± SD.

The mechanism responsible for the low α -galactosidase activity in the heart of patient 1 is unknown, but a consideration of the genetics of this disease may provide an hypothesis. One of the two X-chromosomes is thought to be randomly inactivated at an early stage of normal embryogenesis (17). In Fabry's disease, however, most females have revealed intermediate levels of α -galactosidase A activity and intermediate levels of Gb₃ accumulation. The α -galactosidase A gene has been located to the q22-q24 region on the long arm of the X-chromosome (18). Three possible mechanisms can be proposed to explain various lysosomal enzyme α -galactosidase A activities as shown in Table 3. First, since the inactivation of the X-chromosome is thought to occur before tissue differentiation, the components in the primordial cell may change in subsequent development of each organ. Different proportions of cells might be expressed in a Fabry phenotype to yield variations in the residual α -galactosidase activity among tissues. Second, cells with normal α -galactosidase activity and cells with a defective enzyme may have different viabilities in vivo. Romeo and Migeon (16) reported that fibroblasts obtained from Fabry heterozygotes formed two distinct clonal populations in culture, one with normal and the other with deficient enzyme activity. In the case of X-linked adrenoleukodystrophy (ALD), the mutant allele was shown to give a selective growth advantage to cultured skin fibroblasts from the ALD heterozygote (19). We observed that, in cultured fibroblasts of Fabry heterozygotes, the residual α -galactosidase activity gradually increased with the number of passages in culture (Hozumi, I., unpublished data) suggesting selection favoring the normal allele. Differences in enzyme activities among tissues must be explained by other factors such as the extracellular environment. Third, inactivation of the X-chromosome may be a nonrandom process (20). A female with muscular dystrophy was recently shown to have specific X-chromosome translocations with the breakpoint at Xp 21 (21). In that patient, the normal X-chromosome seemed morphologically inactive. In our patient, such nonrandom activation process may lead to differences in α -galactosidase A activities.

The nucleotide sequence of cDNA of the structural gene encoding α -galactosidase A has recently been determined (22). Similar analyses of cDNA in Fabry's disease are now in progress in our laboratory. There may be point mutations, deletions, or mutation in the regulatory sequence. At present, no information is available on the relationship between the abnormality of the chromosome and preferential inactivation. The α -galactosidase gene in our patient is presently being analyzed for any abnormality. The reason for a different organotypic pattern in involvement between male and female Fabry's patients remains unclear. The study on Fabry heterozygote may provide some clues to answer these problems. ■■

Patients were informed of and gave consent to all biopsies and the use of biopsy materials in this study. We thank our patients for their cooperation. We would like to thank Drs. W. T. Norton and F-C. Chiu, Department of Neurology and Department of Neuroscience, Albert Einstein College of Medicine, for their helpful advice; Drs. A. Yokoyama and A. Shibata, Department of Internal Medicine, Niigata University School of Medicine, Dr. Y. Horikawa, Department of Neurology, Shinrakuen Hospital, Drs. T. Takakuwa and T. Uchikoshi, Department of Pathology, St. Marianna University School of Medicine, and Dr. H. Tunoda, Department of Pathology, Niigata Center Hospital for supplying materials; Dr. T. Tsuda, Department of Internal Medicine, Niigata University School of Medicine, and Dr. K. Shinozawa, Department of Neurology, Brain Research Institute, Niigata University, for performing clinical examinations. We also thank Ms. T. Sasaki and Ms. I. Morohashi for technical assistance. This work was supported by grants from the Ministry of Health and Welfare and the Ministry of Education, Science, and Culture of Japan.

Manuscript received 14 July 1989 and in revised form 10 October 1989.

REFERENCES

1. Desnick, R. J., and C. C. Sweeley. 1983. Fabry disease: α -galactosidase A deficiency. In *The Metabolic Basis of Inherited Disease*. 5th ed. J. B. Stanbury, J. B. Wyngaarden, D. S. Fredrickson, J. L. Goldstein, and M. S. Brown, editors. McGraw-Hill Book Co., New York. 906-944.
2. Burda, C. D., and P. R. Winder. 1967. Angiokeratoma corporis diffusum universale (Fabry's disease) in female subjects. *Am. J. Med.* **42**: 293-301.
3. Ferrans, V. J., R. B. Hibbs, and C. D. Burda. 1969. The heart in Fabry's disease: a histochemical and electron microscopic study. *Am. J. Cardiol.* **24**: 95-110.
4. Broadbent, J. C., W. D. Edwards, H. Gordon, G. O. Hartzler, and J. E. Krawisz. 1981. Fabry cardiomyopathy in the female confirmed by endomyocardial biopsy. *Mayo Clin. Proc.* **56**: 623-628.
5. Desnick, R. J., R. L. Simmons, K. Y. Allen, J. Woods, C. F. Anderson, J. S. Najarian, and W. Klibit. 1972. Correction of enzymatic deficiencies by renal transplantation: Fabry's disease. *Surgery.* **72**: 203-211.
6. Tanaka, H., K. Adachi, Y. Yamashita, H. Toshima, Y. Koga. 1988. Four cases of Fabry's disease mimicking hypertrophic cardiomyopathy. *J. Cardiol.* **18**: 705-718 (Japanese).
7. Voglino, A., M. Paradisi, G. Dompé, A. O. Muda, and T. Farragiana. 1988. Angiokeratoma Corporis Diffusum (Fabry's disease) with unusual features in a female patient. Light- and electron-microscopic investigation. *Am. J. Dermatopathol.* **10**: 343-348.
8. Colley, J. R., D. L. Miller, M. S. R. Hutt, and H. J. Wallace. 1958. The renal lesion in angiokeratoma corporis diffusum. *Br. Med. J.* **1**: 1266-1268.
9. Hozumi, I., M. Nishizawa, T. Ariga, Y. Inoue, Y. Ohnishi, A. Yokoyama, A. Shibata, and T. Miyatake. 1989. Accumulation of glycosphingolipids in spinal and sympathetic ganglia of a symptomatic heterozygote of Fabry's disease. *J. Neurol. Sci.* **90**: 273-280.

10. Yokoyama, A., M. Yamzoe, and A. Shibata. 1987. A case of heterozygous Fabry's disease with a short PR interval and giant negative T waves. *Br. Heart. J.* **57**: 296-299.
11. Folch, J., M. Lees, and G. H. Sloane Stanley. 1957. A simple method for the isolation and purification of total lipides from animal tissues. *J. Biol. Chem.* **226**: 497-509.
12. Vance, D. E., and C. C. Sweeley. 1967. Quantitative determination of the neutral glycosyl ceramides in human blood. *J. Lipid Res.* **8**: 621-630.
13. Suzuki, K. 1978. Enzymatic diagnosis of sphingolipidosis. *Methods Enzymol.* **50**: 456-488.
14. Kobayashi T., N. Shinnoh, and Y. Kuroiwa. 1984. Metabolism of ceramide trihexoside in cultured skin fibroblasts from Fabry's patients, carriers and normal controls. *J. Neurol. Sci.* **65**: 169-177.
15. Martensson, E. 1966. Neutral glycolipids of human kidney: isolation, identification and fatty acid composition. *Biochim. Biophys. Acta.* **116**: 296-308.
16. Romeo, G., and B. R. Migeon. 1970. Genetic inactivation of the α -galactosidase locus in carriers of Fabry's disease. *Science.* **170**: 180-181.
17. Lyon, M. F. 1962. Sex chromatin and gene action in the mammalian X-chromosome. *Am. J. Hum. Genet.* **14**: 135-148.
18. Shows, T. B., J. A. Brown, A. P. Haley, R. L. Eddy, and M. G. Byers. 1978. Assignment of α -galactosidase (α -GAL) to the q22-qter region of the X-chromosome in man. *Cytogenet. Cell Genet.* **22**: 541-544.
19. Migeon, B. R., H. W. Moser, A. B. Moser, J. Axelman, D. Sillence, and R.A. Norum. 1981. Adrenoleukodystrophy: evidence for X-linkage, inactivation, and selection favoring the mutant allele in heterozygous cells. *Proc. Natl. Acad. Sci. USA.* **78**: 5066-5070.
20. Poppers, H. H., T. F. Wienker, T. Grimm, K. Schroetter, and K. Bender. 1977. Evidence for preferential X-chromosome inactivation in a family with Fabry disease. *Am. J. Hum. Genet.* **29**: 361-370.
21. Lindenbaum, R. H., G. Clarke, C. Patel, M. Moncrieff, and J. T. Hughes. selection favoring the mutant allele in heterozygous cells. *Proc. Natl. Acad. Sci. USA.* **78**: 5066-5070.
22. Poppers, H. H., T. F. Wienker, T. Grimm, K. Schroetter, and K. Bender. 1977. Evidence for preferential X-chromosome inactivation in a family with Fabry disease. *Am. J. Hum. Genet.* **29**: 361-370.
23. Lindenbaum, R. H., G. Clarke, C. Patel, M. Moncrieff, and J. T. Hughes. 1970. Muscular dystrophy in an X:1 translocation female suggests that Duchenne locus is on X chromosome short arm. *J. Med. Genet.* **16**: 389-392.
24. Mattei, M. G., J. F. Mattei, and F. Girand. 1982. X-autosome translocations: cytogenetic characteristics and their consequences. *Hum. Genet.* **61**: 295-309.